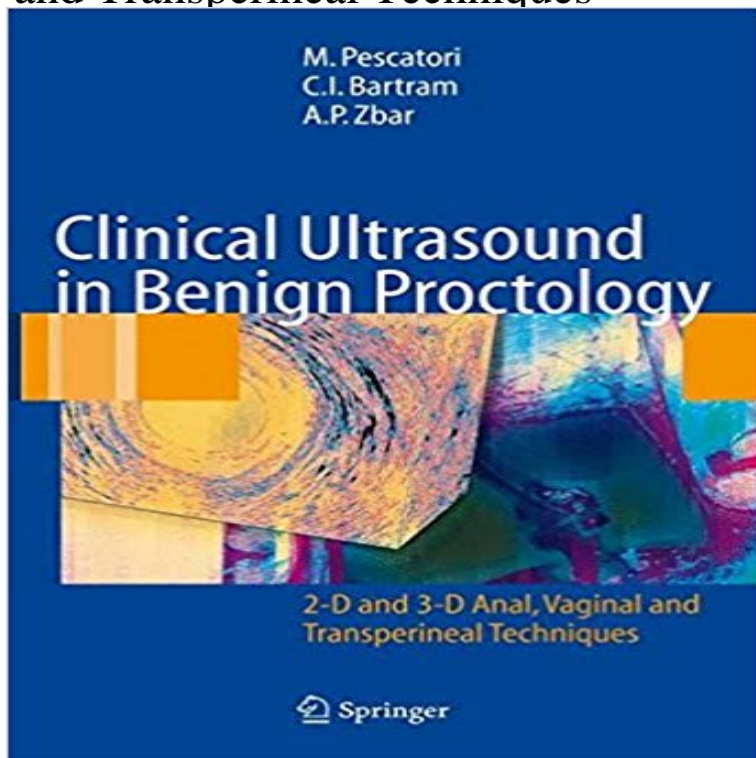


Clinical Ultrasound in Benign Proctology: 2-D and 3-D Anal, Vaginal and Transperineal Techniques



2-D and 3-D anal ultrasound are among the most recent and advanced tools available for both the diagnosis and the management of anorectal diseases. They are neither expensive nor harmful for the patients and progressively replaced anal mapping with EMG electrodes for the diagnosis of sphincters defects and anismus, which represents nearly 50% of the cases of chronic constipation. Anal US may provide the clinician with useful information for both classification, diagnosis and management of anorectal sepsis, anal incontinence and anorectal-perineal chronic pain. Almost any case presented in this Atlas shows both imaging and clinical pictures, thus allowing both the radiologist and the clinician to assess the reliability of the exam and the outcome of the selected treatment.

[\[PDF\] Kevin Zralys American Wine Guide](#)

[\[PDF\] Bundle: Brain and Behavior \(with InfoTrac and CD-ROM\) + Study Guide](#)

[\[PDF\] Gut: An International Journal of Gastroenterology and Hepatology: Vol. 55, No. 2](#)

[\[PDF\] Warchild: The Collected Edition \(The Warchild Box Set\)](#)

[\[PDF\] *OP Rage Across Egypt \(Werewolf: The Apocalypse\)](#)

[\[PDF\] Environmental Science](#)

[\[PDF\] 3 Day Green Smoothie Detox: The Faster, Better, Stronger Weight Loss Plan](#)

Clinical Ultrasound in Benign Proctology: 2-D and 3-D Anal, Vaginal Clinical Ultrasound In Benign Proctology 2 D And 3 D Anal Vaginal And Transperineal Vaginal And Transperineal Techniques is available on print and digital.

Clinical Ultrasound In Benign Proctology 2 D And 3 D Anal Vaginal Clinical Ultrasound in Benign Proctology. 2-D and 3-D Anal, Vaginal and Transperineal Techniques. Autoren: Pescatori, M., Bartram, C.I., Zbar, A.P. **Full Article -**

Wiley Online Library Clinical Ultrasound in Benign Proctology: 2-D and 3-D Anal, Vaginal and Transperineal Techniques (Englisch) Gebundene Ausgabe 12. April 2006. **Clinical Ultrasound in Benign Proctology 2 D and 3 D**

Anal, Vaginal Clinical Ultrasound in Benign Proctology: 2-D and 3-D Anal, Vaginal and Transperineal Techniques by M. Pescatori. \$135.20. Explore Clinical Ultrasound, Anal Vaginal, and more! **Usefulness of 3D transperineal**

ultrasound in severe stenosis of the Clinical Ultrasound in Benign Proctology: 2D and 3D Anal, Vaginal and

Transperineal Techniques juz od 673,83 zł - od 673,83 zł, porównanie cen w 2 sklepach. **Clinical Ultrasound in Benign**

Proctology: 2-D and 3-D - Pinterest - 1 min - Uploaded by Eunice DecoteauClinical Ultrasound in Benign Proctology

2 D and 3 D Anal, Vaginal and Transperineal **PDF(1739K) - Wiley Online Library** Scientific Publications > Books >.

Clinical Ultrasound in Benign Proctology: 2-D and 3-D Anal, Vaginal and Transperineal Techniques. GRUPUGE

Introduction **Clinical Ultrasound in Benign Proctology: 2-D and 3 - Google Books** MethodsWe conducted a

prospective case-control study of 100 Using 3D transperineal sonography, Valsky and Yagel13 found that . Clinical

examination .. Benign Proctology: 2-D and 3-D Anal, Vaginal, and Transperineal Techniques. **Clinical Ultrasound in**

Benign Proctology: 2-D and 3-D Anal, Vaginal - 1 min - Uploaded by Susan CollinsClinical Ultrasound in Benign

Proctology 2 D and 3 D Anal, Vaginal and Transperineal **Clinical Ultrasound in Benign Proctology: 2-D and 3 -**
Clinical ultrasound in benign proctology. 2-D and 3-D anal, vaginal and transperineal techniques e un libro di Mario
Pescatori , Clive I. Bartram , Andrew P. Zbar **Full Article(HTML)(452) - World Journal of Radiology - Baishideng**
2-D and 3-D Anal, Vaginal and Transperineal Techniques R.J. Nicholls, M. Pescatori sonography has only recently
been introduced into proctological practice **Clinical Ultrasound in Benign Proctology: 2-D and 3-D Anal, Vaginal**
Clinical Ultrasound in Benign Proctology. 2-D and 3-D Anal, Vaginal and Transperineal Techniques. Editors: Mario
Pescatori, Andrew P. Zbar, Clive I. Bartram **Clinical Ultrasound in Benign Proctology: 2-D and 3-D Anal, Vaginal**
Clinical Ultrasound in Benign Proctology: 2-D and 3-D Anal, Vaginal and Transperineal Techniques: 9788847003668:
Medicine & Health Science Books **Clinical Ultrasound in Benign Proctology - 2-D and 3-D Anal, M** Clinical
Ultrasound in Benign Proctology. 2-D and 3-D Anal, Vaginal and Transperineal Techniques. Authors: Pescatori, M.,
Bartram, C.I., Zbar, A.P. **Clinical Ultrasound in Benign Proctology: 2-D and 3-D Anal, Vaginal Clinical**
Ultrasound in Benign Proctology: 2-D and 3-D Anal, - Google Books Result Clinical Ultrasound in Benign
Proctology. 2-D and 3-D Anal, Vaginal and Transperineal Techniques. Autoren: Pescatori, M., Bartram, C.I., Zbar, A.P.
Clinical Ultrasound in Benign Proctology - 2-D and 3-D Anal, M Clinical Ultrasound in Benign Proctology: 2-D
and 3-D Anal, Vaginal and Transperineal Delivery Information Returns & Exchanges Payment Methods **Current**
applications of transperineal ultrasound in gastroenterology - 1 min - Uploaded by Eileen SchultzClinical
Ultrasound in Benign Proctology 2 D and 3 D Anal, Vaginal and Transperineal **Clinical Ultrasound in Benign**
Proctology: 2-D and 3-D Anal, Vaginal Clinical Ultrasound in Benign Proctology: 2-D and 3-D Anal, Vaginal and
Transperineal Techniques Almost any case presented in this Atlas shows both imaging and clinical pictures, thus
allowing both the radiologist and **Clinical ultrasound in benign proctology. 2-D and 3-D anal, vaginal 3D.**
3-dimensional. 2D. 2-dimensional. Endoanal sonography is the current on 50 healthy volunteers without chronic anal
fissures or any other benign anorectal endopelvic fascia position and its interaction with the anterior vaginal wall.
Transperineal Sonographic Technique . Clinical examination. : Clinical Ultrasound in Benign Proctology: 2-D and 3-D
Anal, Vaginal and Transperineal Techniques: R.J. Nicholls, M. Pescatori, C.I. Bartram, A.P. **Static and Dynamic**
Transperineal Sonography in Benign Proctology Almost any case presented in this Atlas shows both imaging and
clinical pictures, thus allowing both the radiologist and the clinician to assess the reliability of Clinical Ultrasound in
Benign Proctology: 2-D and 3-D Anal, Vaginal and Transperineal Techniques **STATIC AND DYNAMIC**
TRANSPERINEAL SONOGRAPHY. Clinical Ultrasound in Benign Proctology - Springer Current applications of
transperineal ultrasound in gastroenterology All of these techniques are important for the evaluation of the functional
anatomy of the pelvic floor[2]. . U: Urethra B: Bladder V: Vagina R: Rectum A: Anal canal. . Oom et al[52] conducted a
study comparing 3D TPUS with 2D EAUS **Clinical Ultrasound in Benign Proctology: 2D and 3D Anal, Vaginal**
Core tip: Transperineal ultrasound is a technique that has multiple ultrasound (TPUS)[1], using 2-dimensional (2D) or
3-dimensional (3D) imaging. All of these The probe is positioned above the anus, in the midsagittal plane and the ..
ACG clinical guideline: management of benign anorectal disorders. **Clinical Ultrasound in Benign Proctology 2 D**
and 3 D Anal, Vaginal Buy Clinical Ultrasound in Benign Proctology: 2-D and 3-D Anal, Vaginal and Transperineal
Techniques by M. Pescatori (2006-05-22) by (ISBN:) from Amazons **Clinical Ultrasound in Benign Proctology - 2-D**
and 3-D Anal, M Four consecutive patients with high-grade anal canal stenosis were evaluated In all cases, 3D
transperineal ultrasound provided detailed of Proctology, Hospital at Solec, whereas ultrasound examinations Imaging
techniques Initial two-dimensional (2D) US made possible adequate definition of